

---

---

---

---

# Vulvar Lichen Planus

---

ANDREW T. GOLDSTEIN, MD\* and ARIELLE METZ, MD†

\*The Johns Hopkins School of Medicine, Division of Gynecologic Specialties, Department of Gynecology and Obstetrics, Baltimore, Maryland; and †George Washington University School of Medicine, Department of Obstetrics and Gynecology, Washington, DC

## Introduction

Lichen planus (LP) is an inflammatory, autoimmune, mucocutaneous disorder with multiple clinical variants that may involve both keratinized skin and mucosal surfaces. In addition to affecting keratinized skin of the trunk and extremities, LP often affects the oral and vulvovaginal mucosa. Vulvovaginal involvement can be associated with itching, burning, pain, dyspareunia, and destruction of the vulvar and vaginal architecture.

## Etiology and Epidemiology

The most widely accepted theory of the etiology of LP is that it is an autoimmune mucocutaneous disorder in which activated T-cells target basal keratinocytes. Indirect immunofluorescence on the sera of 58 patients with a definitive clinical diagnosis of erosive genital LP showed epidermal-binding, basement membrane zone antibodies in the sera of 62% of affected patients.<sup>1</sup> Additionally, familial cases have been recognized, leading to the identification of some HLA

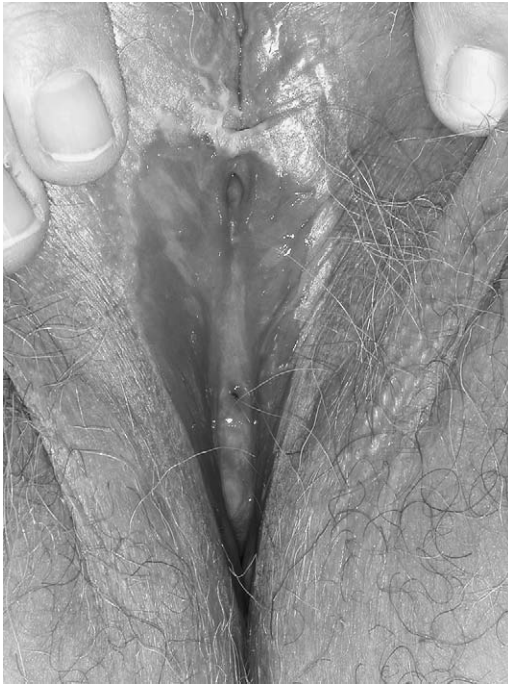associations, including VVG and the HLA-DQBI 0201 allele.<sup>2</sup>

LP affects approximately 1% of all women, most commonly on the oral mucosa.<sup>3</sup> Approximately 25% of women with oral LP also have vulvovaginal involvement.<sup>4</sup> In addition, vulvovaginal involvement is also common in women who have lichen planus of the trunk and extremities. The peak incidence ranges from ages 30 to 60 years.<sup>5</sup> The true incidence of LP is difficult to assess, because affected patients see a variety of specialists (dentists, dermatologists, gynecologists, and at times, gastroenterologists).

## Clinical Variants

Lichen planus can affect the vulva in 3 different clinical variants,<sup>6</sup> the most common form affecting the vulva and vagina is erosive lichen planus. This condition refers to glassy, brightly erythematous erosions associated with white striae known as Wickham's striae<sup>6</sup> (Figs. 1 and 2). LP may involve the labia minora and vestibule in the setting of an otherwise normal vulva, or can be associated with marked architectural destruction, including loss of the labia minora, narrowing of the introitus, and obliteration of the vagina. Vaginal involvement has been reported in up to 70% of patients with erosive

Correspondence: Andrew T. Goldstein, MD, The Center for Vulvovaginal Disorders, 908 New Hampshire Ave. NW, Suite 200, Washington, DC 20037. E-mail: obstetrics@yahoo.com

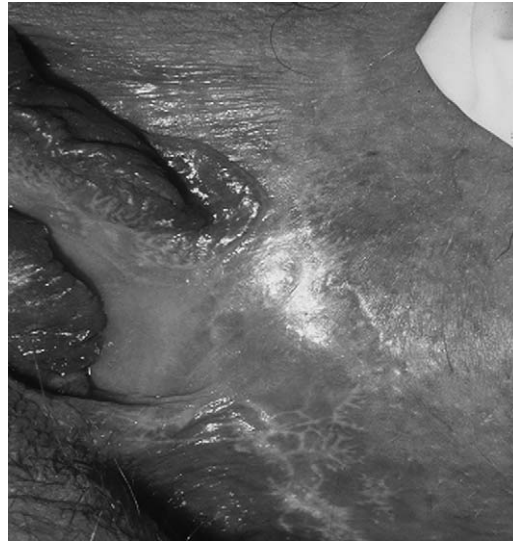

**FIGURE 1.** Erosive lichen planus of the vulva and vagina. Photo courtesy of Andrew Goldstein, MD.

LP.<sup>7,8</sup> Women with erosive LP of the vagina typically have a copious yellowish discharge composed of lymphocytes and immature epithelial cells of the vagina called parabasal cells.<sup>6</sup> The vaginal discharge may also be exudative, pseudomembranous, or serosanguinous.<sup>7</sup> In addition, in cases of severe erosive LP affecting the vagina, synechiae may form between the vaginal walls and may partially, or completely, obliterate the vaginal lumen.

Erosive LP may also appear as part of a syndrome encompassing the triad of erosive or desquamative vulvitis, vaginitis, and gingivitis. This unique constellation of genital and mucosal LP is called the vulvovaginal-gingival syndrome or plurimucosal LP.<sup>9</sup> Lesions affecting different mucosal sites do not necessarily appear contemporaneously.

Other variants of lichen planus may affect the vulva. Papulosquamous LP is classically described as small, intensely pruritic,



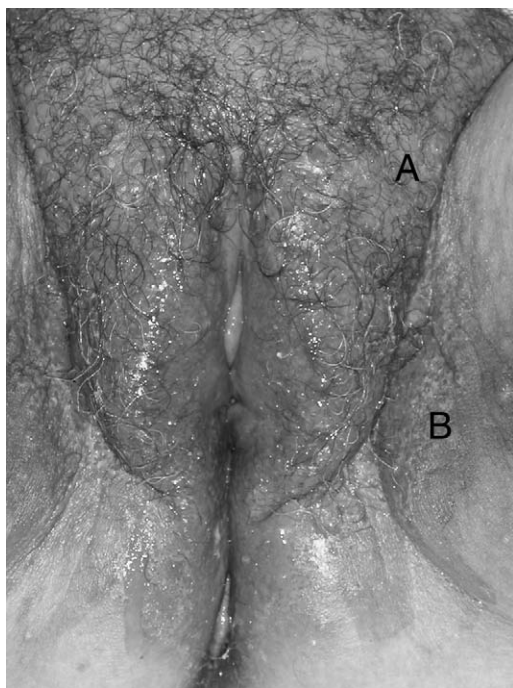
**FIGURE 2.** Wickham's striae. Photo courtesy of Maria Turner, MD.

violaceous papules arising on keratinized skin. More commonly, however, the papules that are present on the vulva and perianal skin are poorly demarcated, pink, and opaque (Fig. 3).<sup>6</sup> Lastly, hypertrophic LP consists of hyperkeratotic, rough lesions involving the perineum and perianal area (Fig. 3). These lesions may resemble squamous cell carcinoma, vulvar intraepithelial neoplasia, or lichen sclerosis.<sup>6</sup>

The histology of erosive lichen planus is lichenoid, indicating a disturbance of the dermal-epidermal interface by a chronic inflammatory infiltrate (Fig. 4). Microscopic examination reveals hyperkeratosis in areas of keratinized skin, irregular acanthosis with a sawtooth appearance of rete ridges, a prominent granular layer, and basal cell liquefaction. Apoptotic eosinophilic basal and prickle cells (colloid bodies) are sometimes present, as is a band-like dermal infiltrate composed primarily of T-cells.

### **Clinical Presentation**

Women with LP typically present with vaginal discharge and with vulvar or vaginal

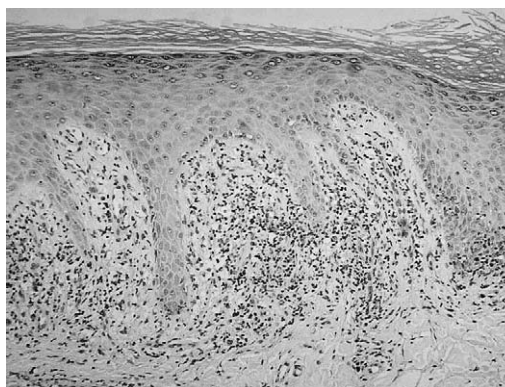


**FIGURE 3.** Hypertrophic lichen planus (A) and papulosquamous lichen planus (B). Photo courtesy of Andrew Goldstein, MD.

discomfort. Intense pruritus, burning pain, dyspareunia, and postcoital bleeding are frequent complaints. On examination, the vulva skin and vaginal mucosa are friable, bleeding easily with speculum insertion. Erosive lesions can be seen in the vagina or on the cervix and, in severe cases, adhesions and synechiae can lead to narrowing and/or obliteration of the vagina. A Papanicolaou test of the vagina or cervix may show atypia. Furthermore, erosive mucous membrane disease can lead to secondary complications resulting from bacterial (staphylococcal or streptococcal species) or fungal (candida) superinfection.<sup>6</sup>

### **Differential Diagnosis**

The differential diagnosis of LP includes several similar inflammatory dermatoses of the vulva. Lichen planus is most commonly



**FIGURE 4.** Histology of lichen planus showing hyperkeratosis, sawtooth appearance of rete ridges, and a band-like infiltrate of T lymphocytes. Photo courtesy of Daniel Skovronsky, MD.

misdiagnosed as lichen sclerosus.<sup>6</sup> Both diseases can have white plaques with an intensely inflammatory reaction on the vulva leading to scarring, agglutination, and destruction of the vulvar architecture. The hyperkeratotic lesions of LP, however, do not typically exhibit the typical waxy or “cigarette paper” appearance of lichen sclerosus. Vaginal involvement is extremely rare in patients with lichen sclerosus. Interestingly, lichen sclerosus and lichen planus can coexist in the same patient.

Erosive LP may also be confused with immunobullous diseases such as mucous membrane pemphigoid, pemphigus vulgaris, and linear IgA bullous disease. These autoimmune diseases can also cause erosions and scarring of the vulva; however, they typically exhibit blisters or bullae that can distinguish them from LP. A punch biopsy taken from the normal tissue at the edge of an erosion and sent for direct immunofluorescence is essential for the diagnosis of the immunobullous diseases and will differentiate between these diseases.<sup>6</sup>

Lichenoid drug reactions and erythema multiforme can also mimic LP. Lichenoid drug reactions are commonly associated with beta-blockers, methyl dopa, penicillamine,

quinidine, nonsteroidal antiinflammatory drugs (NSAIDs), sulfonyleurea agents, carbamazepine, lithium, and quinine. Erythema multiforme is most commonly associated with infectious agents such as herpes simplex virus or drugs such as allopurinol, penicillin, tetracycline, barbiturates, carbamazepine, sulfonamides, or NSAIDs. A thorough medical history and review of systems, therefore, can help distinguish LP for these desquamative disorders.

Papulosquamous LP is most often confused with genital warts or molluscum contagiosum. Histologic examination of the lesions will easily differentiate between these conditions.

### **Treatment**

Unfortunately, the vulvar and vaginal lesions of LP are frequently persistent and resistant to current therapy. It has been suggested that topical medications should be used initially and systemic medication should be reserved for those patients who fail topical medications or those with extensive disease affecting multiple body sites.

The first-line treatment of vulvar LP is the potent or ultrapotent topical corticosteroid ointments such as fluocinonide 0.05% or clobetasol propionate 0.05%.<sup>6</sup> These topical corticosteroids should be used daily until all active lesions have resolved (not to exceed 3 months of daily use) and then the frequency of application and/or the potency of the topical steroid is slowly tapered. Ointments are preferable over creams for the treatment of vulvovaginal LP because creams may contain various substances that are irritating to the tissues. Soaking in warm water before application of steroids may allow better penetration through heavily keratinized lesions.

Vaginal LP can be treated with intravaginal hydrocortisone suppositories that are more commonly prescribed to treat hemorrhoids.<sup>10</sup> Alternatively, vaginal LP can be treated with a potent corticosteroid ointment applied to a vaginal dilator that is then inserted into the vagina. This treats vaginal erosions as well as helping to prevent

obliteration of the vaginal lumen by synechia. These potent corticosteroids should be used sparingly because some authors suggest that occlusive properties of the vagina, combined with its thin mucous membranes, may lead to systemic absorption of these steroids, which may lead to adrenocorticosuppression.<sup>6</sup>

Recently, several studies have reported moderate success treating vulvovaginal LP with tacrolimus,<sup>11-13</sup> a topical macrolide immunosuppressant that is US Food and Drug Administration-approved for the treatment of moderate to severe eczema for adults and children greater than 2 years of age. Tacrolimus inhibits T lymphocyte activity by inhibiting interleukins 2, 4, and 5. Tacrolimus does not affect keratinocytes and does not inhibit collagen synthesis. Therefore, unlike the ultrapotent corticosteroids, tacrolimus does not cause dermal atrophy. As with the ultrapotent steroids, care should be used when using tacrolimus. Tacrolimus can be absorbed through the vaginal mucosa to give serum blood levels high enough to cause systemic immunosuppression when placed with a vaginal applicator. However, neither tacrolimus ointment applied intravaginally with a finger or by suppository produced significant serum levels.<sup>6</sup> Condyloma has been reported in association of the use of tacrolimus, and one could consider decreasing the dose of this medication to 0.03% in such situations.<sup>14</sup>

Topical cyclosporine has also been used for both oral and vulvovaginal LP. Pelisse and colleagues described a series of 12 patients who had a significant reduction in the severity of genital erosions after being treated with topical cyclosporine.<sup>6</sup> Unfortunately, topical cyclosporine is irritating, costly, and difficult to obtain and this limits its usefulness.

If topical medications fail, the first-line systemic treatment is an oral corticosteroid such as prednisone at a dose of 40 to 60 mg per day for a period of 2 to 4 weeks.<sup>6</sup> This regimen will almost always control LP. However, if systemic corticosteroids fail to

control LP, there are reports of several other systemic medications that have successfully treated LP. Whereas none of these medications have been studied in a double-blind, placebo-controlled trials, hydroxychloroquine,<sup>15</sup> oral retinoids,<sup>16</sup> methotrexate,<sup>17</sup> cyclophosphamide,<sup>18</sup> and mycophenolate mofetil<sup>19</sup> have been reported to treat LP. Each of these medications can have serious side effects and should only be used by healthcare providers familiar with their proper use and with the ability to carefully monitor for side effects.

Comfort care measures such as the liberal application of topical emollients such as petrolatum, sitz baths in warm water, and topical anesthetics such as viscous lidocaine can help improve symptoms. Liberal use of oral fluconazole and antibiotics when there is a suspected superinfection can greatly improve systems and the success of treatment.<sup>6</sup> Immediately starting vaginal dilatation can help to prevent obliteration of the vaginal lumen in cases of erosive LP of the vagina. Lastly, because erosive LP can cause severe pain and can cause severe sexual dysfunction, psychologic counseling and sex therapy is often very helpful.

Whereas surgery is not recommended for active lichen planus, it may be necessary to help restore a woman's sexual function when there is severe scarring of the vulvar or vagina. When dilators have failed to open up the vaginal lumen, lasers, hydrodissection, and blunt and sharp dissection have been used to lyse vaginal synechia to restore vaginal patency. However, if active disease is present, these adhesions tend to reform.

### Associations

The potential for malignant transformation in vulvovaginal LP is not well known. Oral LP is clearly associated with increased risk of squamous cell carcinoma, and several case reports have suggested that the same association holds true for vulvovaginal LP.<sup>20–22</sup> In a series of 61 patients with vulvar carcinoma,

3 were found to have the histologically confirmed LP adjacent to the vulvar tumor.<sup>23</sup> Current recommendations encourage regular vulvovaginal examinations in patients with lichen planus and biopsy of any suspicious lesions such as a nonhealing ulcerations or persistent hypertrophy in an area that has been treated with appropriate therapy discussed previously. In addition, patients should be taught vulvar self-examination with a mirror so that they can closely watch for new lesions or architectural changes.

### Conclusion

Vulvovaginal LP is an inflammatory autoimmune mucocutaneous disorder that can cause scarring, pain, sexual dysfunction, and may predispose to vulvar carcinoma. The key to diagnosis is to recognize that LP can have several different clinical variants and can affect both keratinized and mucosal skin of the entire body. Topical steroids remain the mainstay of treatment, but systemic treatment is necessary when there is recalcitrant disease. Comfort care measures can be used to control a patient's symptoms, and early and aggressive vaginal dilators should be used when there is erosive disease in the vagina to preserve vaginal patency.

### References

- Cooper S, Dean D, Allen J, et al. *The Basement Membrane Zone in Genital Erosive Lichen Planus*. British Association of Dermatology; 2003:843–869.
- Setterfield JNS, Ridley M, Vaughan R, et al. The vulvo-vaginal syndrome is associated with the HLA DQB1 \*0201 allele. *Br J Dermatol*. 1996;135:43.
- Eisen D. The clinical features, malignant potential, and systemic associations of oral lichen planus: a study of 723 patients. *J Am Acad Dermatol*. 2002;46:207–214.
- Eisen D. The evaluation of cutaneous, genital, scalp, nail, esophageal, and ocular involvement in patients with oral lichen planus. *Oral Surg Oral Med Oral Pathol Oral Radiol Endod*. 1999;88:431–436.
- Ball SB, Wojnarowska F. Vulvar dermatoses: lichen sclerosus, lichen planus, and vulvar dermatitis/lichen simplex chronicus. *Semin Cutan Med Surg*. 1998;17:182–188.
- Moyal-Barracco M, Edwards L. Diagnosis and therapy of anogenital lichen planus. *Dermatol Ther*. 2004;17:38–46.
- Lewis FM, Shah M, Harrington CI. Vulval involvement in lichen planus: a study of 37 women. *Br J Dermatol*. 1996;135:89–91.
- Ridley CM. Chronic erosive vulval disease. *Clin Exp Dermatol*. 1990;15:245–252.
- Gokdemir G, Baksu A, Taskin M, et al. Vulvovaginal-gingival syndrome of lichen planus: diagnostic and therapeutic challenge. *Aust NZJ Obstet Gynaecol*. 2003;43:389–390.

10. Anderson M, Kutzner S, Kaufman RH. Treatment of vulvovaginal lichen planus with vaginal hydrocortisone suppositories. *Obstet Gynecol.* 2002;100:359–362.
11. Byrd JA, Davis MD, Rogers RS III. Recalcitrant symptomatic vulvar lichen planus: response to topical tacrolimus. *Arch Dermatol.* 2004;140:715–720.
12. Lotery HE, Galask RP. Erosive lichen planus of the vulva and vagina. *Obstet Gynecol.* 2003;101:1121–1125.
13. Kirtschig G, Van Der Meulen AJ, Ion Lipan JW, et al. Successful treatment of erosive vulvovaginal lichen planus with topical tacrolimus. *Br J Dermatol.* 2002;147:625–626.
14. Amstey MS. Erosive lichen planus of the vulva and vagina [Author reply]. *Obstet Gynecol.* 2003;102:645.
15. Eisen D. The therapy of oral lichen planus. *Crit Rev Oral Biol Med.* 1993;4:141–158.
16. Camisa C, Allen CM. Treatment of oral erosive lichen planus with systemic isotretinoin. *Oral Surg Oral Med Oral Pathol.* 1986;62:393–396.
17. Nylander Lundqvist E, Wahlin YB, Hofer PA. Methotrexate supplemented with steroid ointments for the treatment of severe erosive lichen ruber. *Acta Derm Venereol.* 2002;82:63–64.
18. Paslin DA. Sustained remission of generalized lichen planus induced by cyclophosphamide. *Arch Dermatol.* 1985;121:236–239.
19. Frieling U, Bonsmann G, Schwarz T, et al. Treatment of severe lichen planus with mycophenolate mofetil. *J Am Acad Dermatol.* 2003;49:1063–1066.
20. Dwyer CM, Kerr RE, Millan DW. Squamous carcinoma following lichen planus of the vulva. *Clin Exp Dermatol.* 1995;20:171–172.
21. Jones RW, Rowan DM, Kirker J, et al. Vulval lichen planus: progression of pseudoepitheliomatous hyperplasia to invasive vulval carcinomas. *BJOG.* 2001;108:665–666.
22. Lewis FM, Harrington CI. Squamous cell carcinoma arising in vulval lichen planus. *Br J Dermatol.* 1994;131:703–705.
23. Zaki I, Dalziel KL, Solomonsz FA, et al. The under-reporting of skin disease in association with squamous cell carcinoma of the vulva. *Clin Exp Dermatol.* 1996;21:334–337.